Journal of Invertebrate Pathology 105 (2010) 116–119

Contents lists available at ScienceDirect

Journal of Invertebrate Pathology

journal homepage: www.elsevier.com/locate/jip

Short Communication

Wound repair in *Montipora capitata*

Thierry M. Work [a,*], Greta S. Aeby [a,b]

[a] US Geological Survey, National Wildlife Health Center, Honolulu Field Station, PO Box 50167, Honolulu, HI 96850, USA
[b] Hawaii Institute of Marine Biology, PO Box 1346, Kaneohe, HI 96744, USA

ARTICLE INFO

Article history:
Received 12 February 2010
Accepted 9 May 2010
Available online 13 May 2010

Keywords:
Montipora capitata
Healing
Pathology
Scleractinia
Trauma
Coral

ABSTRACT

We documented the microscopic morphology of tissue healing in *Montipora capitata*. Fragments from two healthy coral colonies were traumatized by scraping tissue and skeleton and monitored in flow-through seawater tables every 2–4 days for 40 days for gross and cellular changes. Grossly, corals appeared healed and repigmented by Day 40. Histologically, traumatized issues were undistinguishable from intact untraumatized tissues by Day 12. We suspect that the calicoblastic epidermis of basal body wall is pluripotential and can develop into surface epidermis when needed.

Published by Elsevier Inc.

1. Introduction

A limitation of coral disease investigations has been the lack of standardized biomedical tools to assess coral health. Morphology at the gross and cellular level play a pivotal role in understanding the pathogenesis of coral disease but relatively little information exists on the normal host response of corals to various insults at the cellular level (Work et al., 2008). Healing in response to trauma is a fundamental response of metazoa and has been characterized at the cellular level for a variety of Cnidaria such as soft corals (Meszaros and Bigger, 1999), anemones (Young, 1974; Patterson and Landolt, 1979), and *Hydra* (Tardent, 1963). In soft corals and anemones, wound repair generally involves migration of mesogleal cells to the wound site and re-epithelialization from wound edges. In contrast, studies of healing in scleractinian corals have concentrated on various aspects that affect healing at the gross level such as lesion size and shape (van Woesik, 1998), colony size (Bak and Steward-Van Es, 1980), and temperature (Lester and Bak, 1985). There are currently no published studies on the cellular processes of healing in any scleractinian corals. This is unfortunate because such information could aid microscopic interpretation of lesions from corals collected in the field. Therefore, our objective was to document the mechanisms of healing in *Montipora capitata* that were experimentally traumatized. We chose this species because it is a dominant member of the reef building corals in Hawaii (Maragos et al., 2004) and found throughout the Indo-Pacific (Veron, 2000).

2. Materials and methods

Fragments (ca. 3 cm^2) from a single colony of *M. capitata* manifesting no gross lesions were collected from Kaneohe Bay. Eighty fragments were placed into water tables with flow-through seawater under ambient temperature and natural light. Immediately after collection from the field and placement into water tables, a lesion measuring 0.5 cm^2 wide by 0.5 cm deep was induced in each fragment by scraping tissue and superficial skeleton with a small flat bladed clean screwdriver thereby exposing bare white skeleton and basal body wall. Two replicate fragments were immediately sampled following treatment (Day 0) with two additional replicate fragments subsequently sampled at Days 2, 4, 6, 8, 10, 12, 14, 16, 18, 20, 24, 28, 30, 32, 36, and 40 post-trauma. All sampled fragments were photographed, and fixed in zinc formalin (Anatech, Battle Creek, Michigan, USA) prepared with seawater per manufacturer instructions. Fragments were decalcified in Cal-Ex II (Fisher Scientific, Pittsburgh, Pennsylvania, USA), embedded in paraffin, and sectioned at 5 μm to ensure complete sagittal cross sections of upper and lower body walls at the lesion site. Tissues were stained with hematoxylin and eosin or Masson's trichrome to highlight collagen and examined microscopically. This experiment was repeated a second time with a different coral colony. All experiments were done at the Hawaii Institute of Marine Biology.

3. Results and discussion

Grossly, at Day 0, the lesion appeared white with irregular sharp edges mixed with clumps of mucus and skeleton. By Day 3, edges

* Corresponding author. Address: USGS-NWHC-HFS, PO Box 50167, 300 Ala Moana Blvd. Room 5-231, Honolulu, HI 96850, USA. Fax: +1 808 792 9596.
E-mail address: thierry_work@usgs.gov (T.M. Work).

0022-2011/$ - see front matter Published by Elsevier Inc.
doi:10.1016/j.jip.2010.05.009

of the lesion appeared less distinct but apparently bare white skeleton was evident with subsequent minimal change observed through Day 12. Pigmentation of overlying tissues was evident between Days 12 and 16 and gradually progressed with development of polyps by Day 32. By Day 40, the fragment was essentially healed (Fig. 1). Gross and microscopic findings were similar for the second trial.

With light microscopy at Day 0, basal body wall and mesenterial filaments were exposed (Fig. 2A and B). Between Days 2–4, islands of epidermal regeneration were evident and characterized by clumps of columnar ciliated epithelium interspersed with squamous cells (Fig. 2C and D). These islands of epidermal regeneration seemed to originate from the calicodermis (Fig. 2E) and were evident through Days 6–7. By Day 8, re-epithelialization was essentially complete with expected architecture of epidermis with mucus cells, mesoglea, and gastrodermis that was becoming increasingly populated with zooxanthellae (Fig. 2F). By Day 12, surface body wall was essentially indistinguishable from normal tissue other than fewer zooxanthellae within gastrodermis than normal tissue (Fig. 2G and H). Increase in cellularity such as migration of acidophilic granular amoebocytes, other mesogleal cells, or other inflammatory response was not seen.

Soft corals and anemones have a thick mesoglea, and healing in these organisms is characterized by swelling of mesoglea accompanied by prominent infiltrates of mesogleal cells to the site of injury and re-epithelialization from the edge of the lesion. For example, in the anemone *Anthopleura elegantissima* mixed cellular infiltrates are evident by 48 h (Patterson and Landolt, 1979). In the soft coral *Plexaurella fusifera,* epithelialization of open wounds occurred 1 day after injury and was followed by an axial front of amoebocytes that migrated to the wound site and spread radially to meet with peripheral epithelial cells; healing was complete in ca. 3 weeks (Meszaros and Bigger, 1999).

In contrast, the perforate coral *M. capitata* shows little to no inflammatory response or migration of mesogleal cells to the site of injury, probably in part because the mesoglea in this species is

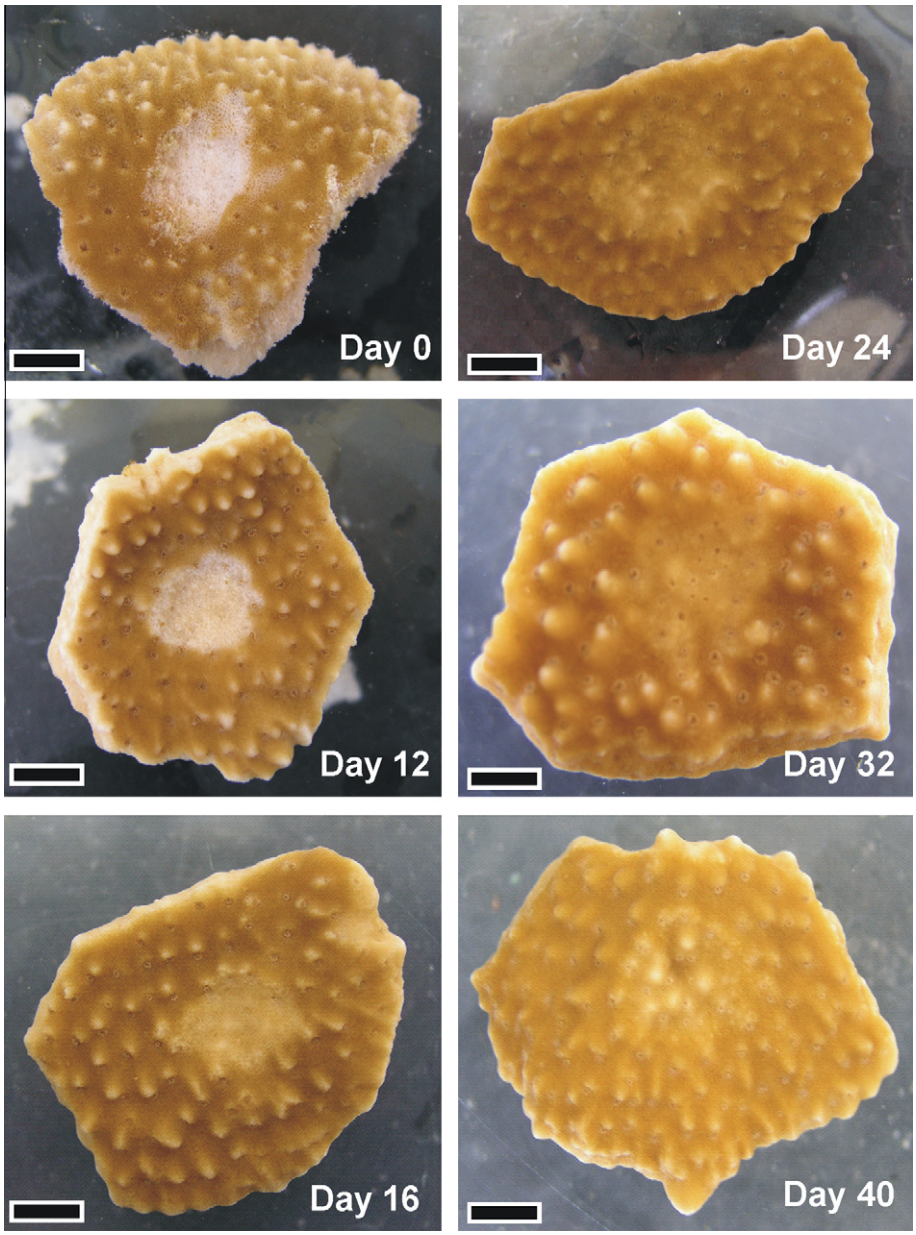

Fig. 1. Fragments of *M. capitata* with experimentally induced trauma showing progression of healing over time. Bar = ca. 1 cm.

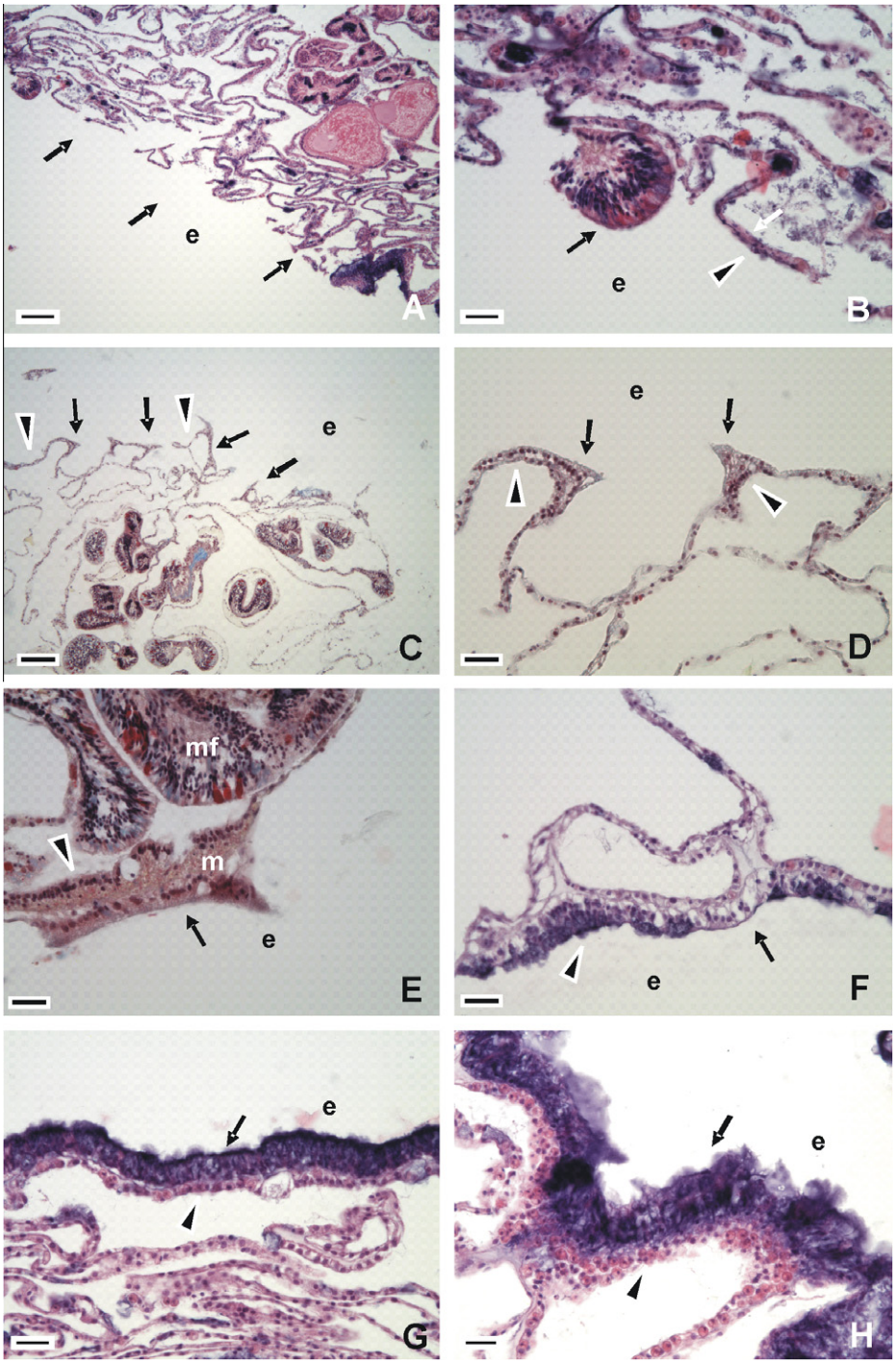

Fig. 2. *M. capitata* tissue sections at Days 0–12 post-injury; all sections at edge of lesions. Sections C and D are stained with Masson's trichrome, whereas the remainder are stained with hematoxylin and eosin. (A) Day 0. Note exposed basal body wall (arrows); Bar = 100 μm. (B) Day 0. Higher magnification of A. Note exposed mesenterial filament (black arrow) and basal body wall composed of gastrodermis (arrowhead) and calicoblastic epidermis (white arrow) separated by thin mesoglea. Bar = 50 μm. (C and D) Day 3. Note islands of columnar cells (arrows) interspersed with basal body wall covered by squamous cells (arrowhead). Bar = 100 μm. (D) Magnification of columnar cells in C (arrows) opposite gastrodermis (arrowhead). Bar = 50 μm. (E) Day 6. Note island of columnar cells mostly lacking mucocytes (arrow) opposite columnar gastrodermis (arrowhead) and swollen mesoglea (m); mf-mesenterial filaments. Bar = 25 μm. (F) Day 8. Note almost complete layer of columnar cells (arrow) with formation of mucus (arrowhead). Bar = 50 μm. (G) Day 12. Note complete epidermal layer with mucus cells (arrow) and colonization of columnar gastrodermis with scant zooxanthellae (arrowhead). Bar = 50 μm. (H) Normal coral (control). Note surface epidermal cells with copious mucous (arrow) and gastrodermis replete with zooxanthellae (arrowhead) separated by thin mesoglea. Bar = 50 μm, e = epidermal surface.

very thin, and the tiny amoebocytes may be difficult to detect (Vargas-Ángel et al., 2007). We think it unlikely that our sampling regimen prevented us from seeing mesogleal cell responses because these are evident in tissues for at least 72 h post-trauma in anemones (Young, 1974; Patterson and Landolt, 1979) and for at least a week in soft corals (Meszaros and Bigger, 1999). The other difference in wound healing between *M. capitata* and other cnidarians studied to date is the formation of islands of columnar cells from exposed basal body wall as early as Days 2 and 3 after injury. These incipient islands of columnar cells often arise opposite the gastrovascular

canals suggesting that they could be originating from the calicodermis which is normally composed of a single layer of squamous cells. By Day 12, these have formed into an intact epidermis composed of columnar cells mixed with mucocytes separated from underlying gastrodermis by a thin mesoglea that is largely indistinguishable from epidermis of uninjured surface body wall. The presence of islands of columnar cells suggests that multiple sites of epidermal regeneration are present during healing, and that migration of epidermal cells from the edges of the lesion is not as important in healing for *M. capitata* as it is for anemones (Young, 1974; Patterson and Landolt, 1979) or soft corals (Meszaros and Bigger, 1999). The availability of a rich cellular tissue matrix deep in the skeleton of the perforate *M. capitata* is probably partly responsible for this difference. Reproducing experimental lesions in a coral like *M. capitata* to replicate studies such as those of Meszaros and Bigger (1999), where all cellular tissues are removed would be impractical even with methods such as waterpiking (Johannes and Wiebe, 1970). We suspect that migration of tissues from the edge of the lesion would play a more important role in non-perforate scleractinia such as *Acropora* or *Pocillopora*. Unlike Meszaros and Bigger (1999), we did not see qualitative increases in zooxanthellae at the site of wound repair.

Determining whether or not islands of columnar cells in regenerating tissues of *M. capitata* originate from calicodermis will require molecular markers that can distinguish calicodermis from epidermal cells for *M. capitata* but these are not yet readily available. However, the morphologic changes described here should be useful to interpret histology of field-collected specimens of *M. capitata*; presence of islands of columnar cells could be indicative of regenerative response to traumatic or other insults. Whereas tissue regeneration in *M. capitata* is essentially complete by Day 12 at the microscopic level, at the gross level, the lesion did not appear completely healed until 40 days. It thus becomes important for investigators looking at healing in corals to distinguish processes at the gross versus the cellular level because they proceed at very different time scales and may differ for imperforate versus perforate coral species.

Acknowledgments

Esther Peters and Valerie Boschler kindly provided constructive comments on earlier drafts. We are grateful to Bob Rameyer and Renee Eismueller for technical assistance. Mention of products does not imply endorsement by the US Government.

References

Bak, R.P.M., Steward-Van Es, Y., 1980. Regeneration of superficial damage in the scleractinian corals *Agaricia agaricites* f. *purpurea* and *Porites asteroides*. Bull. Mar. Sci. 30, 883–887.

Johannes, R.E., Wiebe, W.J., 1970. Methods for determination of coral tissue biomass and composition. Limnol. Oceanog. 15, 822–824.

Lester, R.T., Bak, R.P.M., 1985. Effects of environment on regeneration rate of tissue lesions in the reef coral *Montastrea annularis* (Scleractinia). Mar. Ecol. Prog. Ser. 24, 183–185.

Maragos, J., Potts, D., Aeby, G., Gulko, D., Kenyon, J., Siciliano, D., VanRavensway, D., 2004. The 2000–2002 rapid ecological assessment of corals in the Northwestern Hawaiian Islands. Part I. Species and distribution. Pacific Sci. 58, 211–230.

Meszaros, A., Bigger, C., 1999. Qualitative and quantitative study of wound healing processes in the coelenterate, *Plexaurella fusifera*: spatial, temporal, and environmental (light attenuation) influences. J. Invert. Pathol. 73, 321–331.

Patterson, M., Landolt, M., 1979. Cellular reaction to injury in the anthozoan *Anthopleura elegantissima*. J. Invert. Pathol. 33, 189–196.

Tardent, P., 1963. Regeneration in the Hydrozoa. Biol. Rev. 38, 293–333.

van Woesik, R., 1998. Lesion healing on massive *Porites* spp. corals. Mar. Ecol. Prog. Ser. 164, 213–220.

Vargas-Ángel, B., Peters, E.C., Kramarsky-Winter, E., Gilliam, D.S., Dodge, R.E., 2007. Cellular reactions to sedimentation and temperature stress in the Caribbean coral *Montastraea cavernosa*. J. Invert. Pathol. 95, 140–145.

Veron, J.E.N., 2000. Corals of the World. Australian Institute of Marine Science and CRR Qld Pty Ltd., Townsville, Qld., Australia. 489 pp.

Work, T.M., Richardson, L.L., Reynolds, T.R., Willis, B.L., 2008. Biomedical and veterinary science can increase our understanding of coral disease. J. Exp. Mar. Biol. Ecol. 362, 63–70.

Young, J.A., 1974. The nature of tissue regeneration after wounding in the sea anemone *Calliactis parasitica* (Couch). J. Mar. Biol. Assoc. UK 54, 599–617.